

# Using High Definition Ultrasound to assess the healing rate associated with Long Fibre Carbon Dressings

Dr S Young. In Control Cambridge, S Gray. & S Hampton. Wound Care Consultants. Eastbourne


## Introduction

The aim of this study was to illustrate the benefit of including ultrasound as an assessment tool of wounds when using Long Fibre Activated Carbon (LFAC).

High Definition Ultrasound (HDU) provides quantitative information about what is happening beneath the wound surface, i.e. the wound bed where healing is initiated. Combining this information with that gained from the clinical data undertaken by skilled nurse assessors, looking at surface characteristics, we can get the whole picture of what's happening with the healing status of the wound.<sup>[1-3]</sup>

The scanner operates at a frequency of 20MHz (Episcan - Longport Inc.). This frequency gives an axial resolution of 60µm.

The product used for this study was a long fibre activated carbon dressing (Zorflex). LFAC has been used against bacterial and chemical warfare for armed forces uniforms for many years. Natural progression would offer the same protection in wound care. *In vitro* tests, (UK Health Protection Agency), have demonstrated that LFAC is both antiviral and virucidal, with virus kill rates of 98%. Although LFAC has been used in wound care for many years its complete value in healing had never been established. The aim of this study was to demonstrate the benefits of LFAC through the use of HDU in addition to standard clinical data.



## Method

This was a clinical evaluation of 20 subjects with chronic wounds for minimum of 5 weeks prior to commencement. Subjects were their own control. The initial assessment was carried out then their standard care was continued over a further 5 weeks.

Assessment was then repeated to establish if healing occurred with their standard care. If healing had occurred then the patient was discounted. If not then LFAC applied, a detailed clinical assessment was carried out after 2 weeks, 5 weeks and 12 weeks, as well as HDU scanning.

The scanning procedure required each wound to be exposed and an aqueous gel applied to the wound and a scan taken. Care was taken to always carry out subsequent scans in the same area at each assessment. Scans were also taken of the patient's uninjured skin adjacent to the wound site to get a profile of what the patient's uninjured skin looks like. This is shown in figure 1.

Using the scanners image analysis software it was possible to measure the amount of oedema within the wound tissue. Scans of the wound were then compared to the scans of the uninjured skin to give us a measure of how far from the uninjured state the tissues were at the start of the study and how they then progressed back towards the uninjured profile as the study advanced.

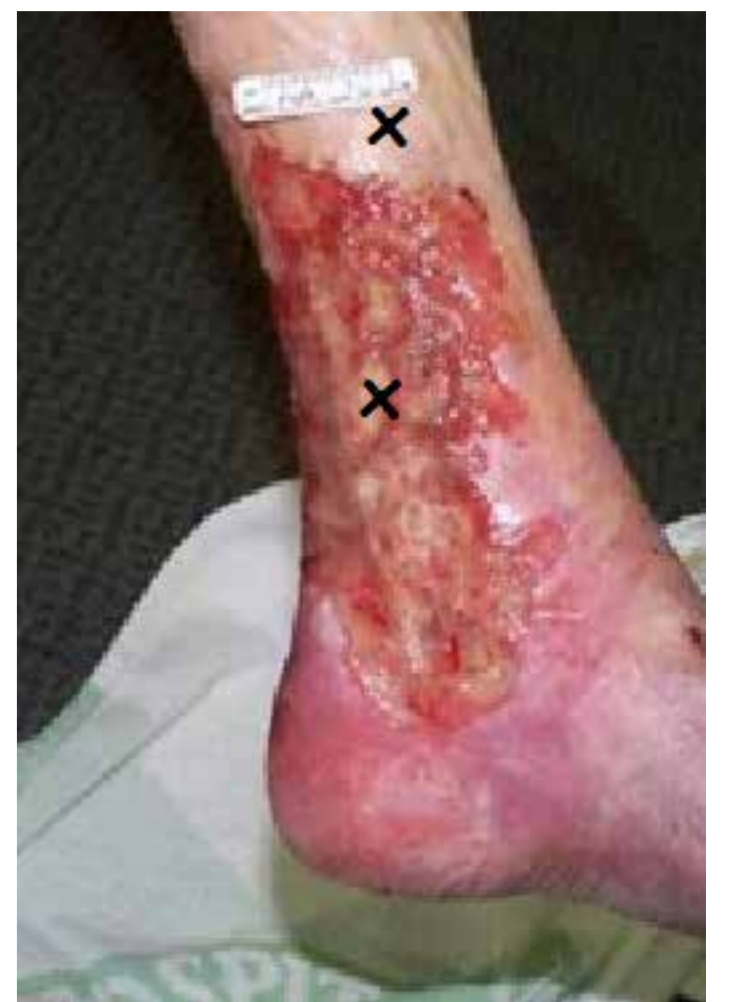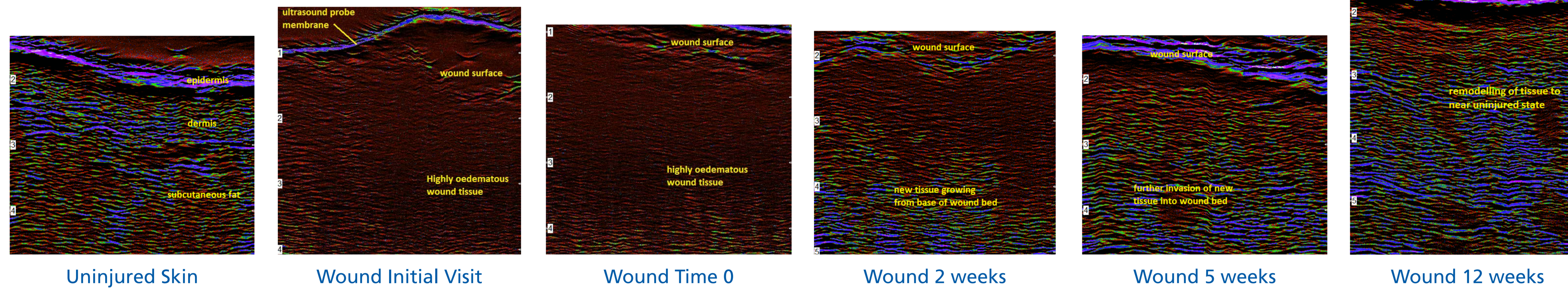


Figure 1

## Results

The results of the wound bed scans show that as treatment progresses the wound area moves towards the uninjured skin profile as inflammation starts to subside and oedema moves out of the area leaving healthy granulation tissue. Figure 2 shows a typical example of this.

Figure 2



At commencement of the study the wound area is shown predominantly in red pixels referred to as Low Echogenic Pixels (LEPs), whereas at the end of the study (week 12) there is an increase in blue pixel number, which is more typical of the uninjured tissue state.

Results of the wound scan analysis (table 1 and figure 3) shows that the ratio of LEP's to total pixel count (TP) is reducing back towards normal uninjured skin levels.

Table 1. LEP / TP Analysis Data

	Normal skin	Wound initial visit	Time 0	2 weeks	5 weeks	12 weeks
Mean LEP/TP	0.453961	1.23186	1.257943	0.977558	0.808359	0.675635
SD	0.0853	0.14392	0.11603	0.08803	0.097328	0.036353

## Statistical Analysis

The data fell into paired sample t-test format, as paired readings are present for individual patients. All calculations were done using Excel. The results are shown in table 2.

Time period comparison	Significant	p-value
Normal vs. Initial	YES	<0.00001
Initial vs. Time 0	NO	=0.06966
Time 0 vs. 2 weeks	YES	<0.00001
2 weeks vs. 5 weeks	YES	=1.6E-05
5 weeks vs. 12 weeks	YES	<0.00001
12 weeks vs. Normal	YES	<0.00001

## Conclusion

Results of the wound scan analysis clearly showed that the ratio of LEPs to TP count reduced back towards normal uninjured skin levels. This data backs the clinical findings that showed patients experience and LFAC demonstrated strong ability to reduce significant associated pain and malodour, effectively cleaning the wound and allowing healing over 7 to 14 days. Within the first week most wounds showed a visually improved surface, with healthier tissue, less non-viable tissue present. 100% wounds healed with LFAC within the 5 week period.

## Discussion

The completion of this study demonstrated the value of HDU in demonstrating healing rates using LFAC for the management of chronic and static wounds. Allowing the clinician to see beneath the wound surface and to be able to quantify this information allowing statistical analysis of the data is of major benefit when assessing a wound care product.

## References

- Young S, Hampton S, Martin R. (2013). Non-invasive assessment of Negative Pressure Wound Therapy using high frequency diagnostic ultrasound: oedema reduction and new tissue accumulation. International Wound Journal. 10(4) 383-388
- Quintavalle P, Lyder CH, Mertz PJ, et.al. Use of high-resolution, high frequency diagnostic ultrasound to investigate the pathogenesis of pressure ulcer development. Adv. Skin & Wound Care 2006; 19(9):498505
- Gniadecka M, Quistorff B. Assessment of dermal water by high-frequency ultrasound: comparative studies with nuclear magnetic resonance. Br J Dermatol. 1996; 135:218-22

Figure 3 Graph of LEP: TP ratio

