

# A RETROSPECTIVE STUDY TO EVALUATE THE EFFECT ON AN ACTIVATED CARBON DRESSING ON CHRONIC WOUNDS

Sylvie Hampton. Independent Tissue Viability Consultant Nurse; Dr Stephen Young. Managing Director, InControl Cambridge; Sarah Gray. Independent Tissue Viability Consultant Nurse.

**Introduction:** The aim of this evaluation: to establish healing associated with long fibre activated carbon (Zorflex) using High Definition 20MHz Ultrasound (HDU), planimetry, pH assessment and photographs. HDU is used to allow quantitative data to be obtained from the tissues underlying the wound surface.

**Method:** The site used was two GP practices in Eastbourne. This was a service evaluation reviewing the use of long fibre activated carbon in clinical practice.

A clinical evaluation undertaken on 22 subjects with 25 chronic wounds that had been non-healing for a minimum of 5 weeks prior to commencement of evaluation. The chronic wounds include venous legs ulcers and diabetic ulcers. The subjects were their own control.

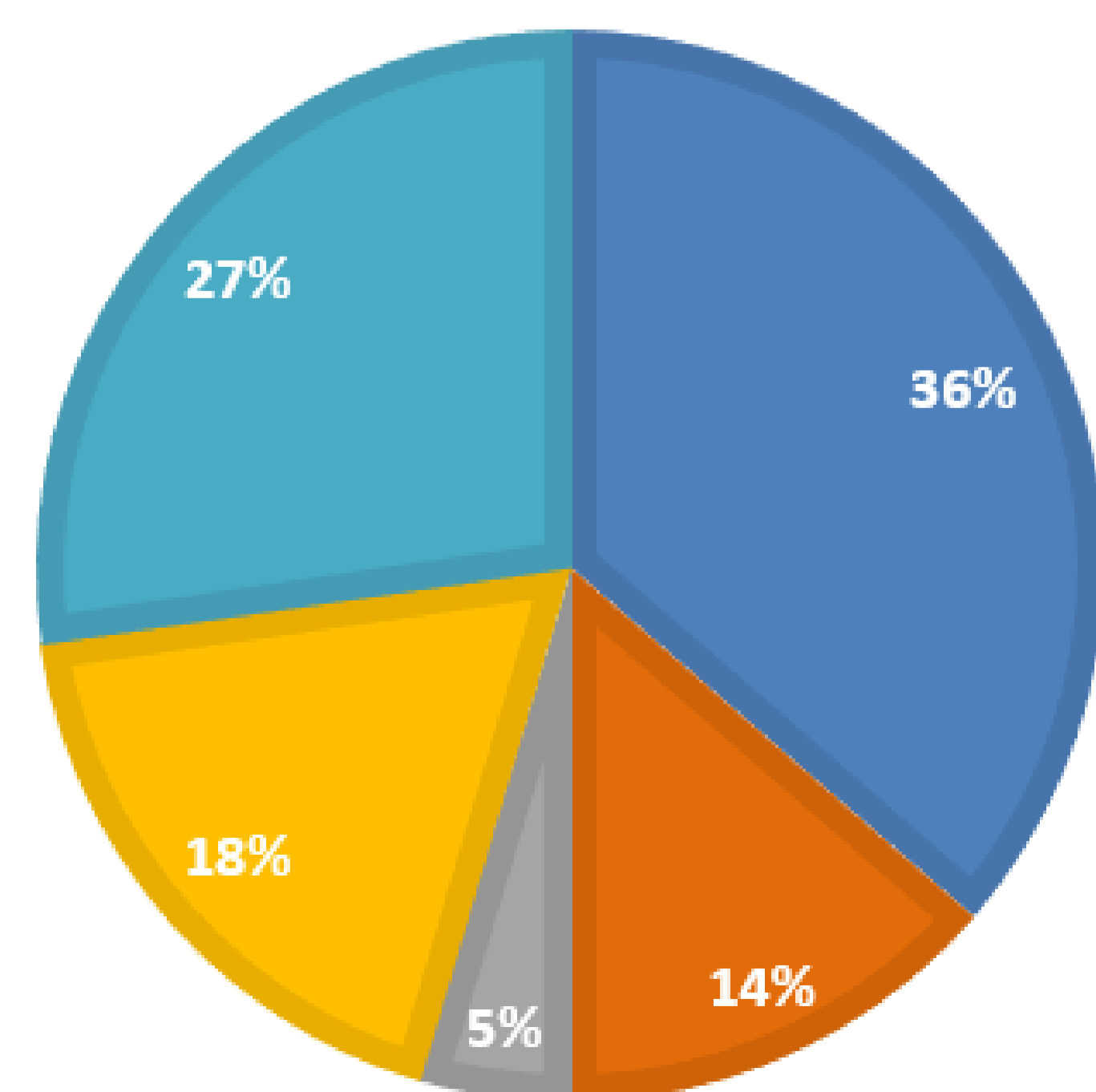
Following informed consent, assessment was undertaken by a Tissue Viability Nurse (TVN) and standard care continued over a further 5 weeks to establish if healing has occurred with standard care. The long fibre activated carbon evaluation was then commenced and HDU, planimetry, pH assessment and photographs were undertaken every 2 weeks.

HDU scanning of wounds was considered an important element to this evaluation as it demonstrates healing beneath the skin to a fraction of an inch. If assessment relied on sight alone, it would be an unreliable result, whereas HDU can be precise and scientific.

The same TVN assessed the wounds at each visit. Long fibre activated carbon, continued until wounds healed.

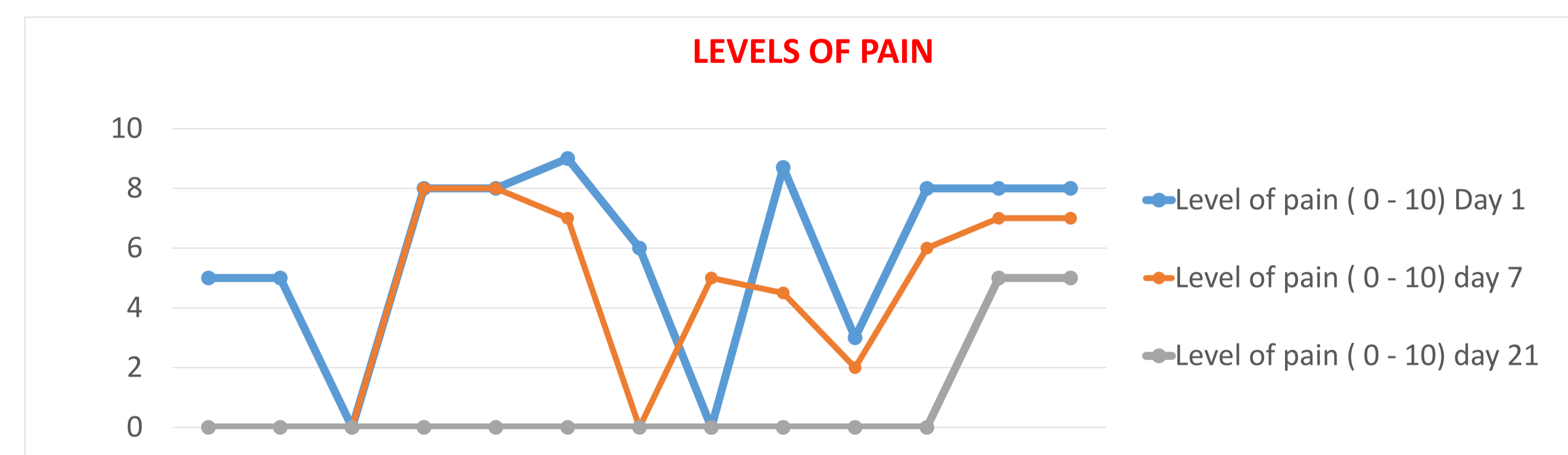
## WOUND TYPES

■ Venous ■ Pressure ■ Fungating ■ Arterial leg ulcer ■ Other



**Results:** The results were as follows: Clinic 1. The wounds all healed 100% in between three weeks and 12 week period. Clinic 2 is ongoing, but the wounds that were evaluated with Zorflex all healed within the same period as clinic 1. The results are shown with t test, photographs and HDU results.

Pain reduction was also seen during the evaluation. The pain was judged on a scale of 1 to 10 with 10 being the worst pain that could be experienced. On the first assessment, the average level of pain was 6.4 with the highest pain being 8 in 6 and 9 in 2 patients. The lowest level of pain was 1 in these 13 patients. On the final assessment, pain level was 5 in two subjects only. All 21 patients at the end were 0 (no pain).



**Discussion:** This product has been used for over 25 years in wound care but has not been used without additives. This evaluation used just the product and this has shown the benefits of long fibre activated carbon when used on its own. This particular product is black in colour and some clinicians may find it difficult to use simply because the colour is not as usual wound care products. However, this should not stop clinicians from seeing the benefits when they do use it.

An observation shows Zorflex seems to keep bacteria at bay while in use, but when it is stopped, the wounds can become colonised with *Pseudomonas*. The answer to that is simple. The product should be used until closure is almost achieved.

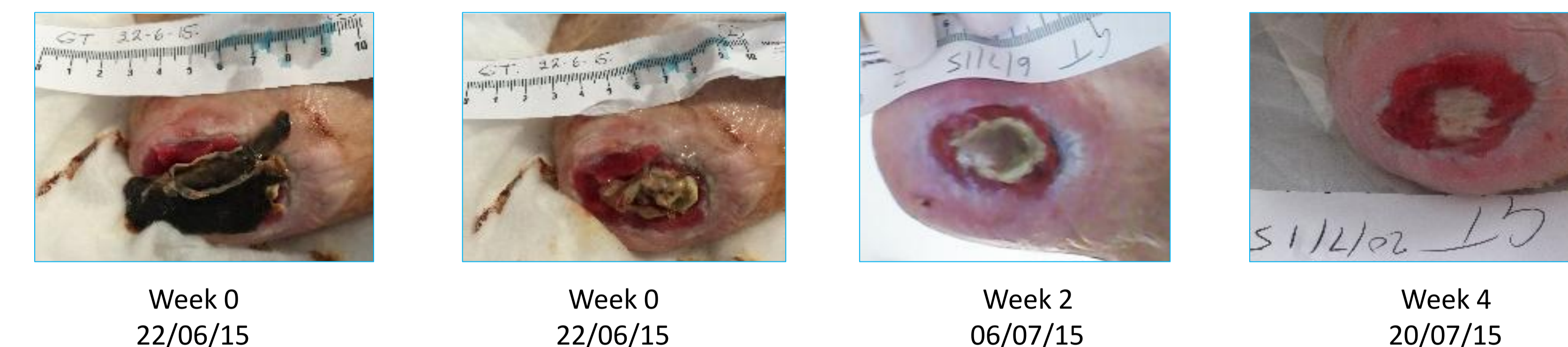
Another observation is that, once the wound has achieved almost full closure and has reached the 'dry' stage just before healing, Zorflex may adhere to the wound bed. This can easily be removed with hydrotherapy or with applying a hydrogel for one week.

**Conclusion:** There is strong evidence for promoting the use of Zorflex for the management of chronic non-healing painful wounds.

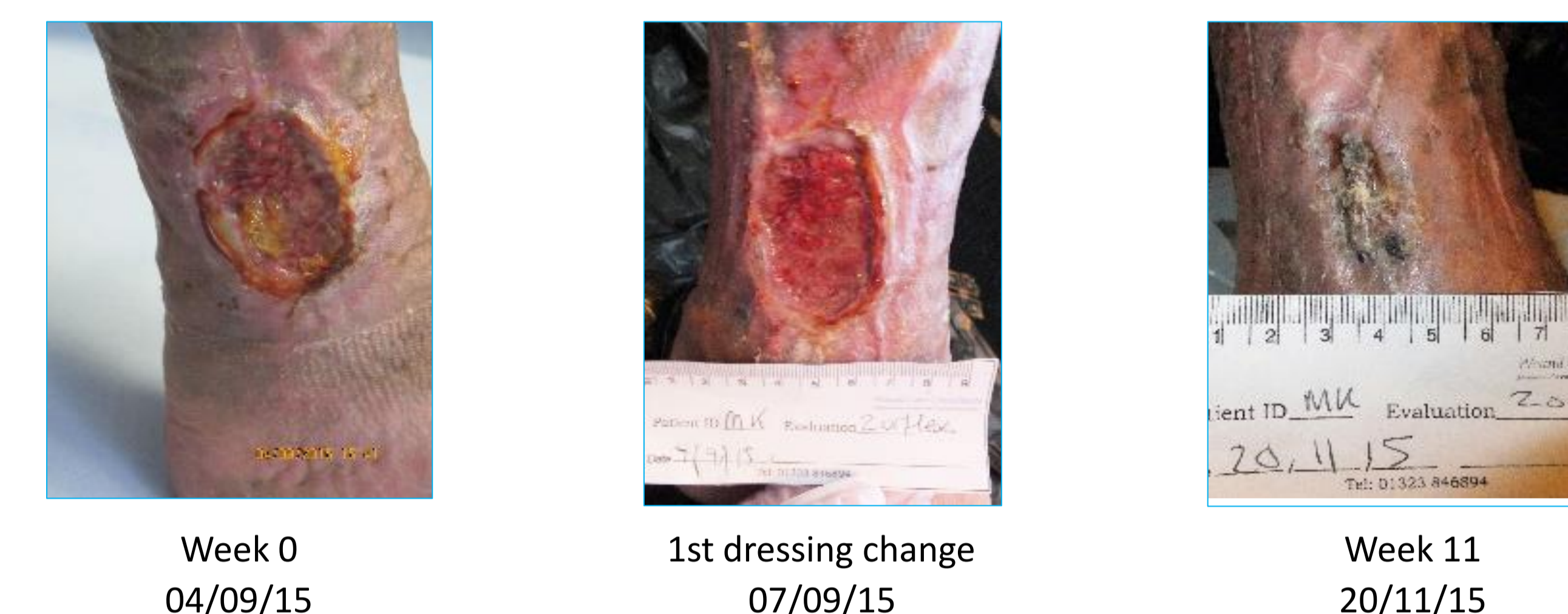The results from the HDU will be presented separately at Wounds UK 2016.

**References:** Hampton. S., Young S. and Kerr A. (2008). Treating Sinus Wounds. Journal of Community Medicine. June 2008, vol. 22. Issue 06.  
Tadej, M., Bree-Aslan, C., Hampton, S., Knowles, A. The irresistible force of long fibre activated carbon cloth on colonised wound outcomes. EWMA, May 2014, 17 page 20.

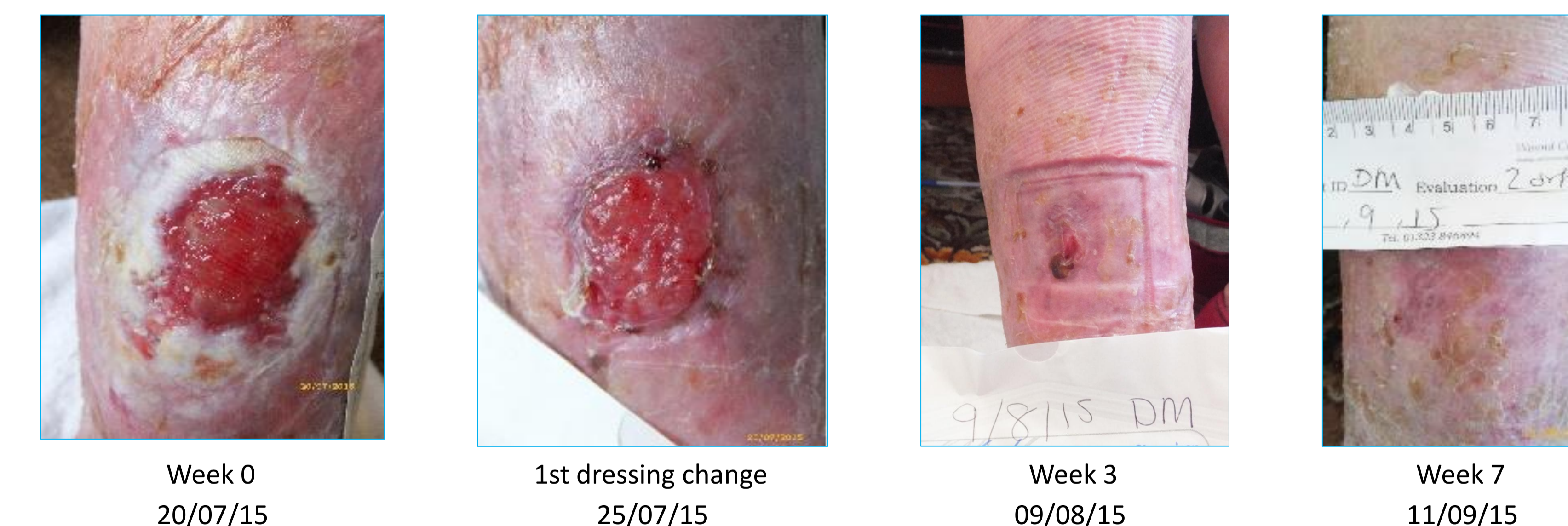
## Samples of patients from the evaluation



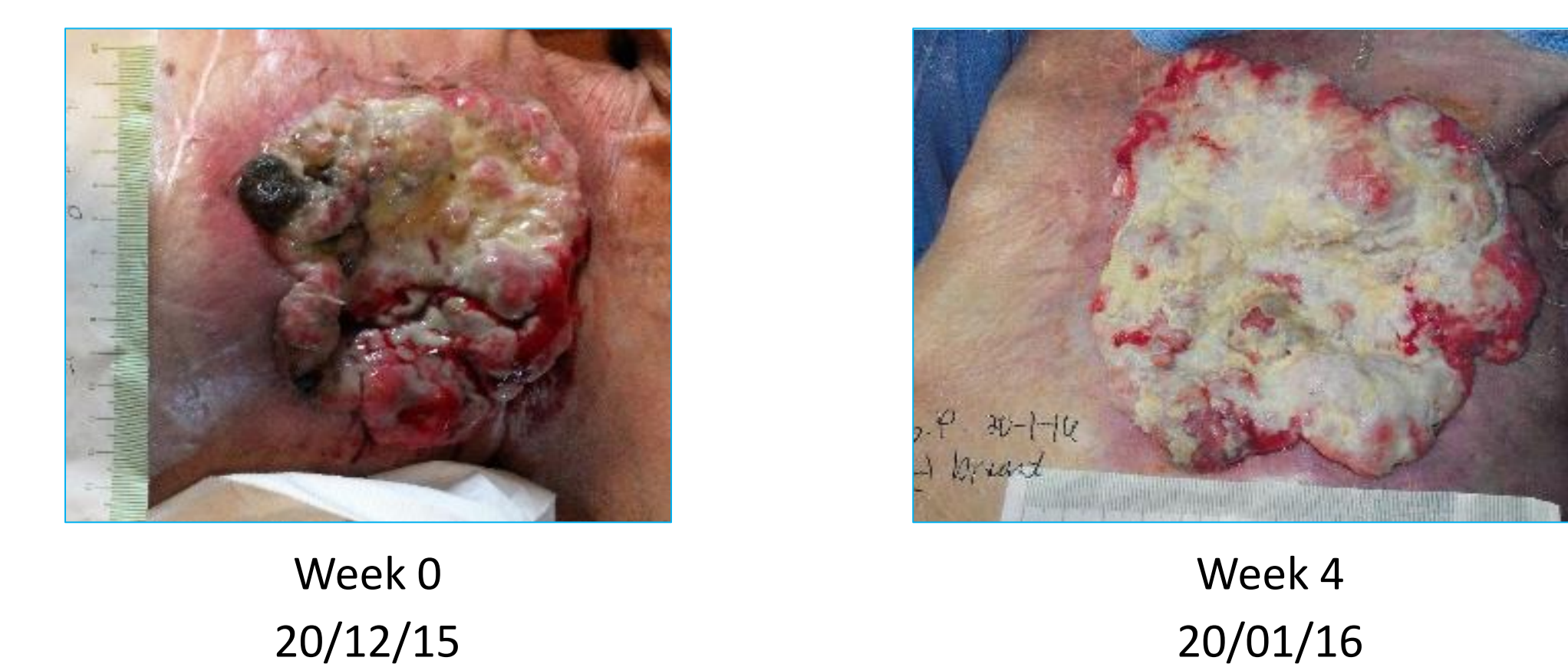Mr GT. Sharp debrided on day 1. Left foot. Healing well.



Mrs MK. Wound duration 3 months prior to application of Zorflex. Reached full closure.



Mrs DM self treated the wound previously for one year. Complete closure achieved with Zorflex.



This fungating breast wound is unlikely to ever heal but the odour has been controlled with Zorflex and the wound is cleaner with less exudate.